



Case Report

Arrhythmia-Induced Cardiomyopathy. A Palestinian Experience

Abdelrhman Janem¹, Aya Zazo², Afnan W. M. Jobran¹

¹ Faculty of Medicine, Al Quds University, Jerusalem, Palestine

² Faculty of Medicine, Aleppo University, Aleppo, Syria

* Corresponding author: afnanjobran26@gmail.com

ABSTRACT

A 20 year-old male was admitted with a history of recurrent palpitations from 5 years. Baseline ECG revealed premature ventricular contractions (PVCs) with delta waves. Stress ECG showed short non-sustained Ventricular tachycardia (VT). Echocardiography showed moderate dilation of the left ventricle with mild reduced systolic function and Ejection fraction was estimated to be 42%. Right ventricle was mildly dilated and hypokinetic. Both atria were mildly dilated. The patient referred to CVC for EP study with possible ablation. The ablation of the focus led to complete suppression of the ectopy. Post-procedure ECG and echocardiography showed normalized rhythm and systolic function.

Article history:

Received 16 may 2022

Accepted 1 August 2022

Available online 30 December 2022

<https://doi.org/10.47723/kcmj.v18i3.853>

Keywords: Arrhythmia, palpitations, ECG



This article is an open access article distributed under the terms and conditions of the Creative Commons Attribution (CC BY) license

<http://creativecommons.org/licenses/by/4.0/>

Introduction

Arrhythmias have been long considered part of the clinical presentation of heart failure (HF) and cardiomyopathy (CM) (1). The hallmark of this condition is partial or complete reversibility once arrhythmia control is achieved. (2). Arrhythmia Induced Cardiomyopathy (AIC) can be classified into 2 categories: one where the arrhythmia is the sole reason for ventricular dysfunction (arrhythmia-induced), and another where the arrhythmia exacerbates ventricular dysfunction and/or worsens HF in a patient with concomitant heart disease (arrhythmia-mediated) (2). Arrhythmia-induced cardiomyopathy is a reversible form of left ventricular (LV) systolic dysfunction caused by a high burden of atrial or ventricular arrhythmias (3). Tachycardiomyopathies (TCMP) are an important

cause of left ventricular (LV) dysfunction that should be recognised by physicians as they are potentially reversible and have a significant impact on morbidity and prognosis (4).

Case Presentation

A 20-year-old male patient with a history of recurrent palpitations from 5 years. These palpitations only appear during slight activity and not during rest. The patient is not a smoker, not alcoholic, has had free personal and familial medical history and was previously not under any medical treatment.

On admission, his respiratory rate was 18 breaths per minute with an oxygen saturation of 98% on room air. His blood pressure was 130/70 mmHg with normal jugular venous pressure. On

auscultation, he had dual heart sounds with no murmurs. However, the heart rate heard was irregularly regular. Baseline ECG showed premature ventricular contractions (PVCs) with delta waves. Short non-sustained Ventricular tachycardia (VT) was detected on stress ECG. By measuring the distance between interventricular septum and anterior wall Echocardiography showed moderate dilation of the left ventricle with moderately reduced systolic function and Ejection fraction was estimated to be 42%. Right ventricle was mildly dilated and hypokinetic. Both atria were mildly dilated. Estimated PAP was 37mmHg (normally <20 mmHg)[5]. In addition, there is mild mitral and tricuspid regurgitation. A tachycardia-induced cardiomyopathy related to ventricular arrhythmia was suspected although a primitive dilated cardiomyopathy complicated by ventricular arrhythmia was initially not excluded. So, the patient was referred to Cardiovascular center (CVC) for electrophysiological (EP) study with possible ablation.

SPGT, SGOT, INR, BILIRUBIN, BUN and CREATININE were tested, and all of them were in the normal range.

During the EP study, detailed mapping of the right ventricular outflow tract (RVOT) and left ventricular outflow tract (LVOT) during PVCs using the Ensite precision 3-D mapping system was done. the earliest evaluation site (>300 ms ahead of the QRS) was reported between the right and left coronary cusps. Several Radiofrequency(RF) lesions were delivered at the earliest site with transient effect. The successful ablation attempt was done by curving the ablation catheter into the aortic root, this maneuver resulted in a good contact. After the ablation, the Patient was monitored on ECG in Coronary care unit and discharged the next day since his ECG was normalized. He was discharged on Ramipril 5mg (1/2x1) and Bisoprolol 5mg (1x1) for one month.

During the follow up after 1 month, his palpitations were progressively improved. Baseline and stress ECG were performed, that showed no abnormalities. Echocardiography was also performed, and revealed an improvement of both LVF and EF; the EF was increased from 42% to 52%. when the EF was 42 , the LV diastolic diameter was more than 65 mm , when it was 52, the LV diastolic diameter was less than 50 mm when it was 55, the LV diastolic diameter was approximately 45 mm So he discharged on the same dose of Ramipril (5 mg (1/2/1)), but taper the dose of Bisoprolol to 2.5 mg (1x1) for 11 months.

After 12 months, his palpitations nearly disappear, with no new changes on the normal baseline and stress ECG from the previous visit. Also, his LVF and EF further improved; in which EF was increased from 52% to 55%. So he discontinued both Ramipril and Bisoprolol without any complications.

Stress and abnormal ECG shown in figure1 and 2.

Discussion

This case report exhibits that PVCs can lead to arrhythmia induced cardiomyopathy (AIC). Serious arrhythmia that causes cardiomyopathy can initiate different organ dysfunction, so it is significant to manage it as soon as possible. [5] The diagnosis of AIC was replaced by "idiopathic dilated cardiomyopathy" because of the absence of awareness about AIC.[6] Numerous theories presented the pathophysiology of AIC such as introducing cellular

and molecular processes, cellular processes likely related to myocardial power consumption, cellular calcium metabolism changes, oxidative tension, ischemia, or apoptosis. [7]

Cardiomyopathy is largely associated with long-term PVCs such as in our patient where there was a long-term presence of PVCs. If there was no congenital cardiac dysfunction, PVCs are quite admitted harmless. [7] However, recurring PVCs can prompt a decrease in LV capacity, specifically PVC-initiated cardiomyopathy. [7]

There are several features related to cardiomyopathies, such as PVCs' long-term presence, the absence of symptoms, PVC with an epicardial source, and longer PVC QRS duration. [7]

As PVC ablation repairs the regular LV capacity of the healthy heart, a practical procedure in those situations is completely to control the patient's symptoms of LV impairment and estimate ablation. Furthermore, separate PVCs have a great prognosis in healthy hearts with protected capacity, therefore there is no intention to intercede except important dysfunction occurs. Unfortunately, our patient has signs of LV impairment with an ejection fraction (EF) of 42%, so the ablation was mandatory. [4] Moreover, our patient followed a spironolactone regimen with a selective beta-blocker for several weeks before the ablation but without any improvement.

Frequently, outflow tract VT or persistent PVCs happen without any congenital heart disease. [8]

Radiofrequency ablation is broadly applied in the management of outflow tract VT. Regardless of the way that it might be related to serious coronary collateral damage and constant AV conduction harm. [9] It was used in our patient and improved his symptoms without any complications.

The appearance of myocardial scar showed by cardiovascular magnetic resonance imaging (CMR) may recognize patients who have constant essential cardiomyopathy and may not profit by ablation management. [10] Our patient did not do CMR, although the ablation was effective.

According to the scientific literature, whenever left ventricular pump work is repaired, the survival prognosis is good, as we can see in our patient. Though, one research demonstrated that even the long time after AIC and standardization of left ventricular systolic dysfunction (LVSD) on MRI, moderate left ventricular dilation and ultra-structural myocardial injuries might be shown, thus regular examination is significant regardless of whether there is no malformations in the following weeks or months of the ablation procedure. [11] The five weeks of follow-up for our patient showed a rapid improvement of LV function with a rapid increase in the EF.

Statement of Human and Animal Rights

This article does not contain any experimental studies with human or animal subjects.

Statement of Informed Consent

Informed consent was obtained from the individual participant included in the study.

Funding

None

Conflict of interest

The authors declare no conflicts of interest

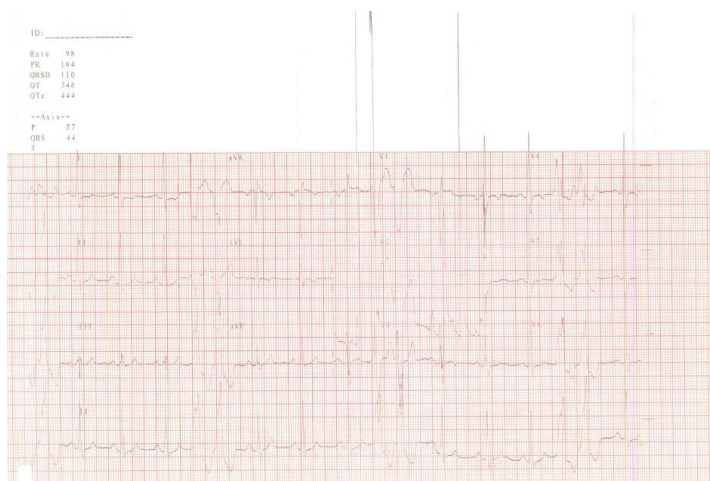

Figure 1: Stress ECG with non-sustained Ventricular tachycardia

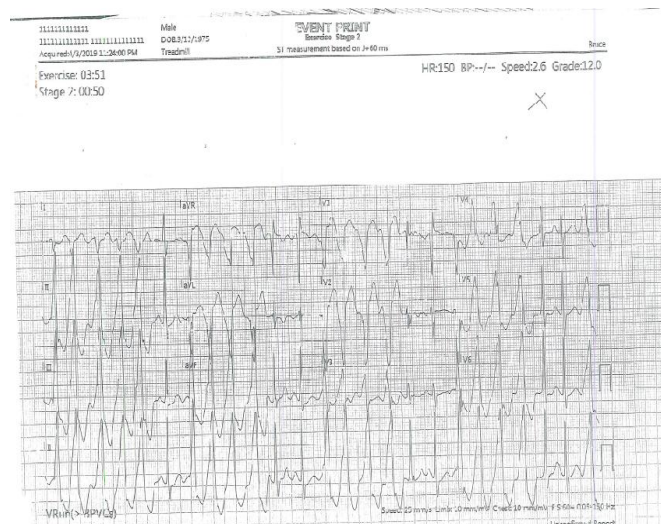


Figure 2: Abnormal ECG showing premature Ventricular contractions (PVCs) in most leads with widespread delta waves

References

- [1] Huizar JF, Ellenbogen KA, Tan AY, Kaszala K. Arrhythmia-induced cardiomyopathy: JACC state-of-the-art review. *Journal of the American College of Cardiology*. 2019;73(18):2328-44.
- [2] Gopinathannair R, Etheridge SP, Marchlinski FE, Spinale FG, Lakkireddy D, Olshansky B. Arrhythmia-induced cardiomyopathies: mechanisms, recognition, and management. *Journal of the American College of Cardiology*. 2015;66(15):1714-28.
- [3] Liuba I, Schaller RD, Frankel DS. Premature atrial complex-induced cardiomyopathy: Case report and literature review. *HeartRhythm Case Reports*. 2020;6(4):191-3.
- [4] Martin CA, Lambiase PD. Pathophysiology, diagnosis and treatment of tachycardiomyopathy. *Heart*. 2017;103(19):1543-52.
- [5] Skinner GJ. Echocardiographic assessment of pulmonary arterial hypertension for pediatricians and neonatologists. *Frontiers in pediatrics*. 2017;5:168.
- [6] Eiringhaus J, Hamer OW, Hollemann D, Brochhausen C, Vollmann D, Maier LS, Sossalla S. The detrimental potential of arrhythmia-induced cardiomyopathy. *ESC Heart Failure*. 2018;5(5):960-4.
- [7] Panizo JG, Barra S, Mellor G, Heck P, Agarwal S. Premature ventricular complex-induced cardiomyopathy. *Arrhythmia & electrophysiology review*. 2018 J;7(2):128.
- [8] Aliot EM, Stevenson WG, Almendral-Garrote JM, Bogun F, Calkins CH, Delacretaz E, Bella PD, Hindricks G, Jaïs P, Josephson ME, Kautzner J. EHRA/HRS expert consensus on catheter ablation of ventricular arrhythmias: developed in a partnership with the European Heart Rhythm Association (EHRA), a registered branch of the European Society of Cardiology (ESC), and the Heart Rhythm Society (HRS); in collaboration with the American College of Cardiology (ACC) and the American Heart Association (AHA). *Europace*. 2009 Jun 1;11(6):771-817.
- [9] Roberts-Thomson KC, Steven D, Seiler J, Inada K, Koplán BA, Tedrow UB, Epstein LM, Stevenson WG. Coronary artery injury due to catheter ablation in adults: presentations and outcomes. *Circulation*. 2009;120(15):1465-73.
- [10] Yalin K, Gölcük E. Frequent premature ventricular contractions and cardiomyopathy, chicken and egg situation. *Journal of Atrial Fibrillation*. 2017;10(2).
- [11] Brembilla-Perrot B, Ferreira JP, Manenti V, Sellal JM, Olivier A, Villemain T, Beurrier D, De Chillou C, Louis P, Brembilla A, Juillière Y. Predictors and prognostic significance of tachycardiomyopathy: insights from a cohort of 1269 patients undergoing atrial flutter ablation. *European Journal of Heart Failure*. 2016;18(4):394-401.

To cite this article: Janem A, Zazo A, Jobran AWM. Arrhythmia-induced cardiomyopathy. A Palestinian Experience . Al-Kindy College Medical Journal . 2022;18(3):246-8.